American Cleft Palate-Craniofacial Association
75th Anniversary

*Clinical/Case Report*

The Cleft Palate-Craniofacial Journal
1-6

DOI: 10.1177/1055665618770053
journals.sagepub.com/home/cpc
SAGE

# An Unusual Case of an Odontogenic Keratocyst Associated With an Ungrafted Alveolar Cleft: A Case Report and Review of the Literature

**Sapna Radia, BDS(Hons), MSc, FDS, RCS(Orth)[1], Alexander C. Cash, BDS, MSc, FDSRCS(Orth)[1,2], and Kanwalraj Moar, BDS, MFDS, MBChB, FRCS(OMFS)[3]**

**Abstract**

We describe an unusual case of an odontogenic keratocyst (OKC) associated with an ungrafted left-sided alveolar cleft in a 10-year-old male patient. There is no previous report in the literature of OKC or other dental cysts associated with an alveolar cleft. We discuss the management of the OKC prior to secondary bone grafting and present this case to highlight the difficulty in the management of OKC concurrent with grafting of the alveolar cleft site, the proximity of unerupted permanent teeth, and possible treatment modalities.

**Keywords**

odontogenic keratocyst, keratocystic odontogenic tumor, cyst, alveolar cleft, keratocyst

## Introduction

Odontogenic keratocysts (OKCs) are benign neoplasms of odontogenic origin. The treatment of OKCs remains controversial with a variety of treatment modalities from simple enucleation to marsupialization or resection. Additionally, the diagnosis of an OKC should arouse suspicion of a potential diagnosis of naevoid basal cell carcinoma syndrome (NBCCS) or Gorlin-Goltz syndrome. The presentation of this patient with an OKC associated with an alveolar cleft is particularly challenging in view of the necessity for bone grafting and the presentation of unerupted teeth. There are also no previous reports of OKC or other dental cysts associated closely with an alveolar cleft. In this report, we will discuss the management we employed relative to the procedures required to restore the alveolar cleft while being aware of providing these for a patient with unerupted teeth adjacent to the site of the pathology.

## Case Report

This 10-year-old male patient was referred for alveolar bone grafting (ABG) to treat a left-sided unilateral cleft lip and alveolus. He also presented with a nonsymptomatic cyst related to the crown of the unerupted UL3 adjacent to the ungrafted left alveolar cleft. His chief complaint was the ability to pass air through the fistula in his alveolus in the cleft site. He was medically well and had undergone primary left-sided lip repair at age 3 months. His family history showed no evidence of reported orofacial clefting, although his maternal uncle had a history of a treated dental cyst and multiple basal cell carcinomas.

His physical examination revealed a left-sided alveolar notch associated with a small buccal fistula with nasal communication. He was in the late mixed dentition with hypodontia of the upper left lateral incisor and retained mildly hypoplastic upper left deciduous lateral incisor and canine (Figure 1).

Radiographic examination in July 2014 revealed the left-sided alveolar cleft and a unilocular radiolucency associated with a displaced maxillary canine adjacent to the cleft (Figure 2). The upper left unerupted canine was ectopic with two-third completed root development, and the upper left lateral incisor was confirmed as missing. Our differential diagnosis included the following: dentigerous cyst, midline inclusion cyst, and incisive canal cyst.

[1] Queen Victoria Hospital, East Grinstead, United Kingdom
[2] South Thames Cleft Service, London, United Kingdom
[3] Cleft Net East, Addenbrooke's Hospital, Cambridge, United Kingdom

**Corresponding Author:**
Kanwalraj Moar, BDS, MFDS, MBChB, FRCS(OMFS), Cleft Net East, Addenbrooke's Hospital, Cambridge, United Kingdom.
Email: kanwalraj.moar@addenbrookes.nhs.uk

**Figure 1.** Intraoral clinical photograph taken in 2014 with the patient aged 10.

Initial plans for treatment involved enucleation of the cyst and removal of the ULB and ULC with alveolar bone graft, with an iliac bone graft if appropriate (August 2014). Figure 3 shows the intraoperative clinical photographs. No buccal bony plate was overlying the cyst, and there was no obvious nasal floor fistula. The cyst, ending at the cementoenamel junction, enveloped the crown of the ectopic upper left canine. The cyst was enucleated and sent for histopathological analysis along with the cyst contents. The alveolar bone graft was not carried out as it was felt to be inappropriate without a conclusive diagnosis of the pathology.

Pathological analysis noted a cyst composed of uninflamed dense fibrous tissue lined by parakeratinized stratified squamous epithelium of 6 to 7 cell layers thick. There was basal palisading and the surface showed corrugations (Figure 4A). The cyst lining showed involution and focal detachment. A daughter cyst was present within the cyst wall (Figure 4B). The histological impression was of an OKC.

The patient was reviewed with the multidisciplinary cleft team and referred to clinical genetics to explore the potential diagnosis of NBCCS, formerly Gorlin-Goltz syndrome, which was subsequently excluded.

The cleft site was subsequently treated with Carnoy's solution in November 2014, and no additional lesion was identified histologically. Due to its fixative nature, particular care was taken to avoid exposure of the nasal lining and tooth root surfaces to the Carnoy's solution. A postoperative dental panoramic tomography taken 6 months post cyst enucleation showed some slight eruption of the ectopic upper left canine and no radiographic evidence of a cyst recurrence. The root of the upper left canine was now three quarter formed (Figure 5).

The patient underwent alveolar bone grafting approximately 6 months after Carnoy's application. At the standard 6-month follow-up, the dental panoramic tomography and upper standard occlusal showed a good bony bridge and further root development of the upper left canine (Figure 6).

Since diagnosis of OKC, the patient has had 6 monthly follow-ups in the cleft multidisciplinary clinic to review potential recurrence of OKC and to review the eruption of the upper left canine. Figure 7 shows no obvious recurrence and some further development of the canine. This tooth is currently being monitored for spontaneous eruption during the early phases of fixed orthodontic care, but the patient has been made aware of the alternative options such as expose and bond should this be required. Following the alignment of the upper left canine follow-ups will initially be extended to an annual basis to monitor for potential recurrences.

## Discussion

There is no previous report in the literature of an OKC or other dental cysts associated directly with an alveolar cleft. Kichenaradjou et al (2010) and Lekkas et al (2001) report inadvertent inclusion of nasal mucosal cells at the time of (secondary) alveolar bone grafting, which later proliferated into a benign inclusion cyst of respiratory epithelial type. Cho et al (2008) also report a cyst developing after (secondary) bone grafting but again diagnosed this as an inclusion cyst associated with a foreign body reaction through histopathological analysis.

### *Odontogenic Keratocysts*

The term OKC has been reinstated by the World Health Organisation (WHO) Working Group 2017 and is now the preferred term replacing the terminology of keratocystic odontogenic tumor (KCOT) (Speight and Takata, 2017). This working group had changed the term OKC to KCOT in 2005 but has now renamed it as OKC (Barnes et al., 2005). The initial alteration to KCOT was implemented to better reflect the neoplastic nature of the tumor rather than that of a benign cystic lesion (Reichart et al., 2006). However, the WHO consensus group has since concluded that Drosophila segment polarity Patched tumour suprressor gene (PTCH) alterations are not specific and further evidence is required to support terminology of a neoplastic origin (Passi et al., 2017). Therefore, the term OKC is now the most appropriate name.

The key clinical features of OKC are the potential for locally destructive behavior, multiplicity, and the recurrence rate. The reasons for recurrence are thought to relate to remnants of the delicate epithelial lining (with its active basal cell layer) being left behind during enucleation or due to the development of a new OKC from a microcyst or an epithelial island left behind in the adjacent mucosa. Sharif et al. (2015) describe "satellite cysts" as derivatives of odontogenic epithelial residues and daughter cysts caused by outpouching of the main cyst lining. Stoelinga (2005) reports that all cases with OKC have epithelial islands and/or microcysts within the overlying attached mucosa and therefore stresses the importance of location and complete removal of the overlying attached mucosa. There is a range of recurrence rates quoted in the literature influenced by the type of treatment modality from 0% to 60% (Stoelinga and Bronkhorst, 1988; Blanas et al., 2000; Shear and Speight, 2007; Kaczmarzyk et al., 2012; Johnson et al., 2013; Sharif et al., 2015). A systematic review by Kaczmarzyk et al (2012) suggests an overall recurrence rate of 23.15% based on 2 retrospective reviews that met the criteria of the review. This systematic review was not able to appraise recurrence rates of specific treatment modalities. The major factor is the

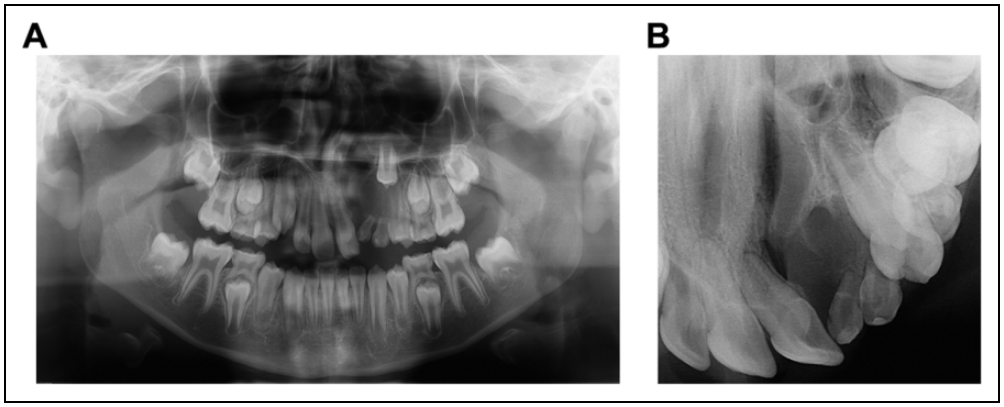


**Figure 2.** Pretreatment dental panoramic tomography (A) and upper standard occlusal (B) taken in July 2014.

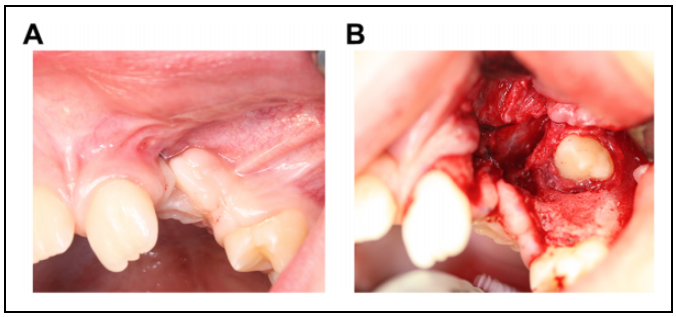


**Figure 3.** Intraoperative clinical photograph pre-enucleation (A) and post-enucleation (B) of cyst in the left alveolar cleft (August 2014).

inadequate follow-up period posttreatment, as although the majority of OKCs recur within the first 5 years following treatment, this could be 10 or more years. Furthermore, other authors included patients with NBCCS within study populations without specifying whether cysts in these patients were new or a recurrence.

In general, there is a spectrum of treatment modalities that are used for the treatment of OKC. These include curettage, marsupialization, enucleation alone, enucleation with Carnoy's solution before enucleation or to the bony cavity after enucleation, enucleation with cryotherapy, enucleation with peripheral ostectomy, and resection (Blanas et al., 2000; Kaczmarzyk et al., 2012).

Our chosen treatment option was enucleation followed by a secondary procedure involving application of Carnoy's solution (ethanol:chloroform:glacial acetic acid in a 6:3:1 ratio). This is a common and acknowledged procedure that carries low morbidity. A second procedure was necessary, because at the time of the first procedure, the diagnosis of OKC was unknown, and in addition, Carnoy's solution was not readily available. Carnoy's solution acts by penetrating superficial cancellous spaces in the defect and thus devitalizes and fixes the remaining tumor cells. According to Stoelinga (2005), a mildly penetrating agent such as this should suffice in eliminating possible vital cells left behind in the defect and therefore reducing recurrence. Recurrence rates with this technique are variable in the literature. In the systematic review by Kaczmarzyk et al (2012), enucleation with Carnoy's application resulted in a 50% recurrence rate. However, this outcome is questionable as it is based on just 2 patients with a mean follow-up of 5.25 years, one of whom developed a recurrence. Stoelinga (2001) reported a recurrence rate of 7.8% in 80 patients and Zhao et al. (2002) reported 6.7% recurrence in 29 patients. Follow-up periods of these 2 studies range from 1 to 29 years. Once again, it is difficult to draw conclusions from these studies as the original description of applying Carnoy's solution into the cyst lumen prior to enucleation is not always followed, as it is often applied to the bony cavity following enucleation (Voorsmit et al., 1981; Blanas et al., 2000). Additionally, following a Food and Drug Administration (FDA) ban in the United States of chloroform in pharmaceutical products, some Carnoy's solution preparations no longer contain chloroform creating confusion in the assessment of recurrence rates. A study in 2015 showed reduced efficacy with the new chloroform-free formulation, with the American Association of Oral and Maxillofacial Surgeons issuing a statement that we should petition the FDA for continued use of the original formulation (Dashow et al., 2015).

Cryotherapy is an alternative to Carnoy's solution and aims to destroy epithelial remnants and/or satellite cysts in the same way while maintaining an intact osseous framework. Schmidt and Pogrel (2001) provide the best available evidence of a series of cases, but the study still has inherent bias for comparison. Theoretically, the ideal treatment for OKCs is the most conservative option with the least morbidity and the least chance of recurrence. Many studies show the lowest recurrence rates with aggressive resection, but at the cost of high morbidity. Stoelinga (2005) is critical of this approach and believes that any epithelial remnants or microcysts lie in the attached mucosa, which needs elimination rather than the surrounding bone In a recent systematic review and meta-analysis by Al-Moraissi et al. (2016), the authors concluded that enucleation with or without adjuvant therapy resulted in 48.6% more reduction in recurrence rate when compared to marsupialization with or without secondary cystectomy. The necessity for prospective, blinded, multicenter studies with long follow-up periods was highlighted (Johnson et al., 2013; Al-Moraissi et al., 2016).

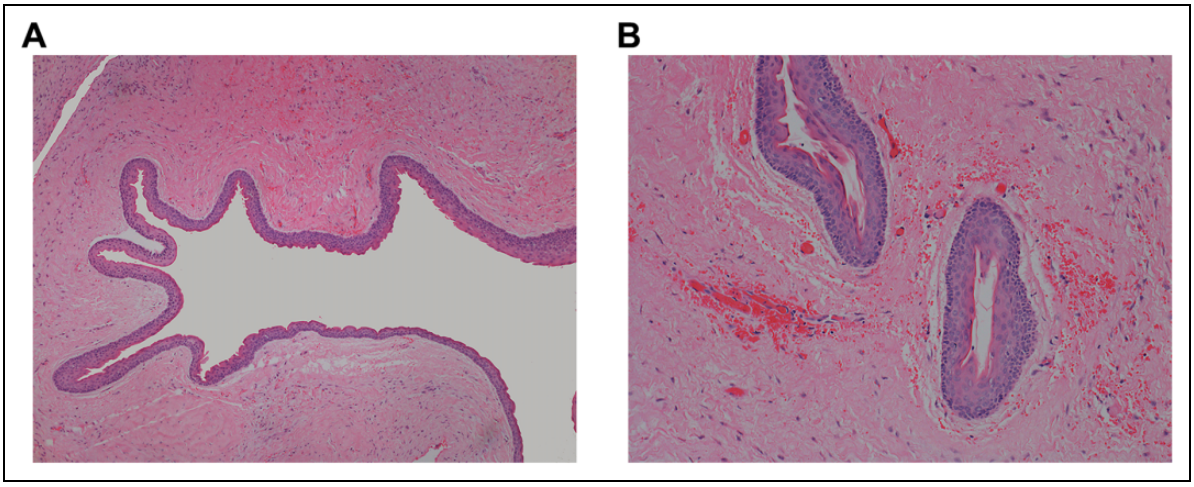


**Figure 4.** A, Slice of cyst showing a thin-folded lining of the cyst composed of parakeratinized stratified squamous epithelium. B, A daughter cyst is seen within the cyst wall.

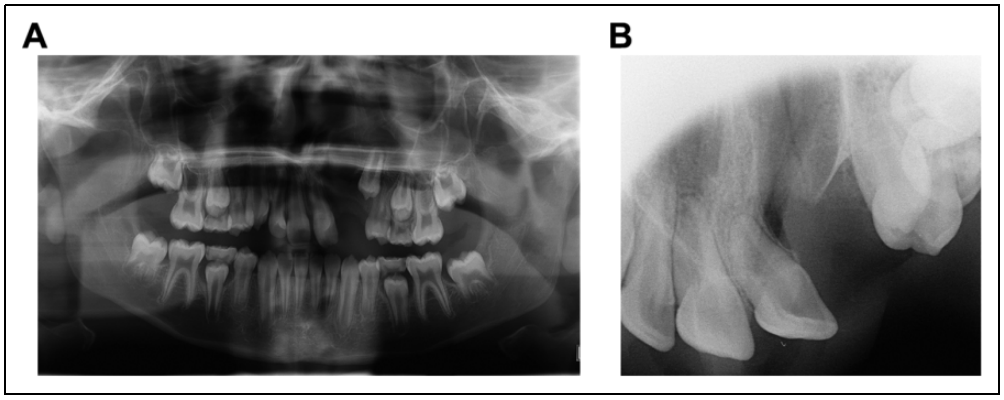


**Figure 5.** Dental panoramic tomography (A) and upper standard occlusal (B) taken in January 2015, 6 months after cyst enucleation.

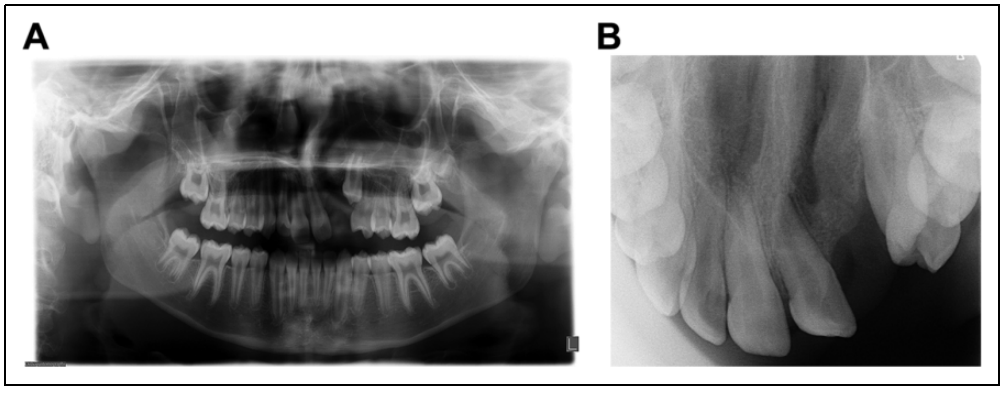


**Figure 6.** Dental panoramic tomography (A) and upper standard occlusal (B) taken in February 2016, 6 months after alveolar bone grafting.

In general, there is uncertainty regarding the optimal treatment modality, which makes treatment decisions particularly challenging. This has been highlighted in the Cochrane Systematic Review, which failed to find any randomized controlled trials that met the trial criteria investigating the effectiveness of interventions for the treatment of KCOT (Sharif et al., 2015). The results are not directly applicable to this case, as in this review, participants under 18 years were excluded as it was understood that most pediatric cases with OKC are associated with NBCCS. The review of treatment modalities of OKC was highlighted as a priority title by the oral and maxillofacial expert panel of the Cochrane Oral Health Group.

Follow-up regimes differ but ideally should be at least annually within the first 5 years following primary surgery.

**Figure 7.** Dental panoramic tomography taken in September 2017, 26 months after alveolar bone grafting.

Thereafter, once every 2 years is a recommended protocol to assess for late-developing recurrences (Stoelinga, 2001, 2005).

### *Naevoid Basal Cell Carcinoma Syndrome*

The patient in this case was sent for genetic testing for NBCCS. Naevoid basal cell carcinoma syndrome, formerly Gorlin-Goltz syndrome, has an array of clinical manifestations including OKCs and cleft lip and palate. Several studies quote the incidence of CLP to be 5% to 8.5% (Soekarman et al., 1991; Lambrecht and Kreusch, 1997; Lo Muzio, 1999). Lambrecht and Kreusch (1997) advocate the investigation of NBCCS in all patients who present with OKCs. There are established criteria for the diagnosis of NBCCS (Lo Muzio, 2008). However, these may not be as informative at evaluating the syndrome within the child population as particular features such as BCCs often do not present until puberty. Particular attention therefore needs to be paid to other diagnostic criteria such as palmar and plantar pits and suggestive facial dysmorphic features (Lambrecht and Kreusch, 1997; Kimonis et al., 2013).

### *Treatment Challenges and Treatment Modalities*

There are several factors in this case that make treatment decisions particularly challenging. Firstly, the proximity of the OKC to the alveolar bone graft site is especially difficult as treatment to the OKC site could have ramifications on the success of the alveolar bone graft and subsequent eruption of the unerupted upper left canine. The potential for recurrence of the OKC is an additional significant challenge as treatment has to be balanced to be appropriately aggressive but with low morbidity and subsequent effect on the alveolar bone graft site. The timing of alveolar bone graft is also of importance as the patient was at the appropriate stage for bone grafting and extensive delay to bone graft could affect the long-term success of alveolar bone grafting. Finally, the aim in this case was to attempt maintenance and alignment of the upper left canine to avoid the potential for prosthetic rehabilitation of a 2-unit space in view of the hypodontia of the upper left lateral incisor. Orthodontic space closure to 1 unit in the case that the upper left canine is lost would be a theoretical possibility, but a challenging one particularly in view of the patients with class III malocclusion and continuing growth.

Our chosen treatment option of enucleation followed by secondary application of Carnoy's solution and subsequent alveolar bone graft was justified as it would theoretically reduce potential recurrences without significant destruction of adjacent tissues leading to a large defect. The disadvantage is the potential effect of Carnoy's solution on the unerupted upper left canine due to the fixative properties of the solution. Application of Carnoy's solution at the time of initial enucleation was not possible as the diagnosis of OKC was not known, and Carnoy's solution was not readily available. Alveolar bone grafting was not completed at the same time as Carnoy's solution application as this could compromise the viability of the bone graft. The radiographic presentation would also be altered following grafting, and therefore, the ability to assess any recurrences would be more complex. The disadvantage of this approach is an additional surgical procedure for the patient. A further surgical procedure to expose and bond a gold chain to encourage closed forced eruption of the canine tooth is possible if it fails to erupt, but this will be contemplated should the need arise. Again, this is not a procedure that could be combined with alveolar bone grafting due to the potential addition of a septic conduit to the immature graft site via the gold chain.

Considering the complexities and challenges of this case, there is merit in appraising the alternative treatment options. Enucleation alone and immediate alveolar bone grafting would be a hypothetical alternative. However, the authors believe this would have significantly increased the possibility of future recurrence and/or the complexity of addressing this should a recurrence occur. In addition, with an unusual presentation at the time of initial exploration, the operating surgeon could not justify immediate ABG with the additional iliac crest site morbidity in light of the potential complications. Peled et al. (1991) describe a similar case report, but in a patient with NBCCS. The patient presented with a KCOT and was being prepared for ABG for the treatment of cleft lip and palate. However, in this patient, the ABG site was on the opposite side of the maxilla to the OKC and therefore did not have the same challenges. The author chose the conservative option of marsupialization of the OKC and attachment of an orthodontic appliance to the ectopic canine. This tooth was subsequently aligned. This was not considered a viable option here as marsupialization would impact the success of the subsequent alveolar bone graft due to the proximity of the sites and the impact on the septic conduit. The alternative use of cryotherapy as an adjunctive was not considered in light of the lack of good quality evidence to reduce recurrence rate. Resection was considered unnecessarily aggressive.

## Conclusion

An unusual presentation of an ungrafted alveolar cleft associated with an OKC was described together with a description of our chosen treatment modality and alternative options. Enucleation of the OKC, application of Carnoy's solution, and bone grafting of the alveolar cleft aimed to prevent the

recurrence of OKC and restore alveolar tissue, prevent nasal fistula, and allow bone for subsequent tooth eruption. Further long-term follow-up is required to determine whether recurrence of the OKC has been successfully avoided. However, there remains no consensus on the general optimal treatment modality of OKC (particularly when associated with alveolar cleft), and this will require further prospective, well-conducted studies to aid future informed treatment choices in these difficult cases.

## Authors' Note

This case report was presented orally at the 10th European Craniofacial Congress, in Gothenburg, Sweden, on June 26, 2015, as well as at the Annual Scientific Conference of the Craniofacial Society of Great Britain and Ireland in London, United Kingdom, on April 16, 2015.

## Acknowledgments

The authors thank Mr Robert Kennedy, histopathologist, for pathological preparation and analysis and Mr Ian Francis, consultant radiologist, for his help with radiographic reporting.

## Declaration of Conflicting Interests

The author(s) declared no potential conflicts of interest with respect to the research, authorship, and/or publication of this article.

## Funding

The author(s) received no financial support for the research, authorship, and/or publication of this article

## References

Al-Moraissi EA, Pogrel MA, Ellis E. Enucleation with or without adjuvant therapy versus marsupialization with or without secondary enucleation in the treatment of keratocystic odontogenic tumors: a systematic review and meta-analysis. *J Craniomaxillofac Surg*. 2016;44(9):1395-1403.

Barnes L, John EW, Reichart P, Sidransky D, eds. *World Health Organization Classification of Tumours, Pathology and Genetics of Head and Neck Tumours*. Lyon, France: IARC Press; 2005.

Blanas N, Freund B, Schwartz M, Furst IM. Systematic review of the treatment and prognosis of the odontogenic keratocyst. *Oral Surg Oral Med Oral Pathol Oral Radiol Endod*. 2000;90(5):553-558.

Cho U, Shigematsu H, Takahashi Y, Watanabe Y, Tanaka A, Sakashita H. A case of inclusion cyst occurring after secondary bone grafting in the alveolar cleft. *Japanese J Oral Maxillofac Surg*. 2008;54(9):526-530.

Dashow JE, McHugh JB, Braun TM, Edwards SP, Helman JI, Ward BB. Significantly decreased recurrence rates in keratocystic odontogenic tumor with simple enucleation and curettage using Carnoy's versus modified Carnoy's solution. *J Oral Maxillofac Surg*. 2015;73(11):2132-2135.

Johnson NR, Batstone MD, Savage NW. Management and recurrence of keratocystic odontogenic tumor: a systematic review. *Oral Surg Oral Med Oral Pathol Oral Radiol*. 2013;116(4):e271-e276.

Kaczmarzyk T, Mojsa I, Stypulkowska J. A systematic review of the recurrence rate for keratocystic odontogenic tumour in relation to treatment modalities. *Int J Oral Maxillo Surg*. 2012;41(6):756-767.

Kichenaradjou A, Beale VR, Haers PE. Cystic change in alveolar bone graft. *Int J Oral Maxillofac Surg*. 2010;39(6):615-616.

Kimonis VE, Singh KE, Zhong R, Pastakia B, DiGiovanna JJ, Bale SJ. Clinical and radiographic features in young individuals with naevoid basal cell carcinoma syndrome. *Genet Med*. 2013;15(1):79-83.

Lambrecht JT, Kreusch T. Examine your orofacial cleft patients for Gorlin-Goltz syndrome. *Cleft Palate Craniofac J*. 1997;34(3):342-350.

Lekkas C, Smets LMH, Van Hoeken F. Cyst arising in a free bone graft. *Eur J Plastic Surg*. 2001;24(4):195-196.

Lo Muzio L, Nocini P, Bucci P, Pannone G, Consolo U, Procaccini M. Early diagnosis of nevoid basal cell carcinoma syndrome. *J Am Dent Assoc*. 1999;130(5):669-674.

Lo Muzio L. Nevoid basal cell carcinoma syndrome (Gorlin syndrome) Orphanet. *J Rare Dis*. 2008;3:32.

Passi D, Singhal D, Singh M, Mishra V, Panwar Y, Sahni A. Odontogenic keratocyst (OKC) or keratocystic odontogenic tumor (KCOT)—Journey of OKC from cyst to tumor to cyst again: comprehensive review with recent updates on WHO classification. *Int J Curr Res*. 2017;9(7):54080-54086.

Peled M, Kohn Y, Laufer D. Conservative approach to unerupted teeth within cystic lesions in gorlin's syndrome. *Am J Ortho Dentofacial Orthop*. 1991;99(4):294-297.

Reichart A, Philpsen H, Sciubba J. The new classification of head and neck tumours (WHO)—any changes? *Oral Oncol*. 2006;42(8):757-758.

Ruprecht A, Austermann KH, Umstadt H. Cleft lip and palate, seldom seen features of the Gorlin-Goltz syndrome. *DentomaxillofacRadiol*. 1987;16(2):99-103.

Schmidt BL, Pogrel MA. The use of liquid nitrogen cryotherapy in the management of odontogenic keratocysts. *J Oral MaxillofacSurg*. 2001;59(7):720-725.

Sharif FN, Oliver R, Sweet C, Sharif MO. Interventions for the treatment of keratocystic odontogenic tumours. *Cochrane Database Syst Rev*. 2015;(11):CD008464.

Shear M, Speight PM. Odontogenic keratocyst. In: Shear M, Speight PM, eds. *Cysts of the Oral and Maxillofacial Regions*. 4th ed. Oxford, England: Blackwell Munksgaard; 2007:6-58.

Soekarman D, Fryns JP, Casaer P, Berghe H Van Den. Increased head circumference and facial cleft as presenting signs of the nevoid basal-cell carcinoma syndrome. *Genet Couns*. 1991;2(3):157-162.

Speight PM, Takata T. New tumour entities in the 4th edition of the world health organization classification of head and neck tumours: odontogenic and maxillofacial bone tumours. *Virchows Arch*. 2017. doi:10.1007/s00428-017-2182-3.

Stoelinga PJW, Bronkhorst FB. The incidence, multiple presentation and recurrence of aggressive cysts of jaws. *J Craniomaxillofac Surg*. 1988;16(4):184-195.

Stoelinga PJ. The treatment of odontogenic keratocysts by excision of the overlying, attached mucosa, enucleation, and treatment of the bony defect with Carnoy solution. *J Oral Maxillofac Surg*. 2005;63(11):1662-1666.

Stoelinga PJW. Long-term follow-up on keratocysts treated according to a defined protocol. *Int J Oral Maxillofac Surg*. 2001;30(1):14-25.

Voorsmit RA, Stollinga PT, Van Hallst VJ. The management of keratocysts. *J Maxillofac Surg*. 1981;9(4):228-236.

Zhao YF, Wei JX, Wang SP. Treatment of odontogenic keratocyst: a follow-up of 255 Chinese patients. *Oral Surg Oral Med Oral Pathol Oral Radiol Endod*. 2002;94(2):151-156.